Funktionelle Myodiagnostik der AK

Schulter

1. Rhomboidei
2. Serratus ant.
3. Supraspinatus
4. Infraspinatus
5. Teres minor
6. Subscapularis
7. Deltoideus (ant., med., post.)
8. Langer Bizepskopf
9. Levator scapulae
10. Trapezius med.
11. Trapezius inf.
12. Trapezius sup.
13. SCM
14. Subclavius
15. Pectoralis minor
16. Latissimus
17. Teres major
18. Pectoralis major sternalis (PMS)
20. Coracobrachialis
21. Triceps brachii, langer Kopf

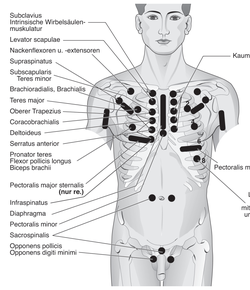

NL-Reflexzonen Armmuskeln

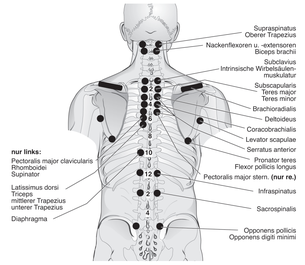

Kaumuskulatur

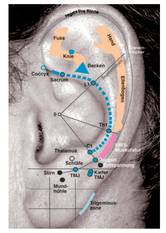

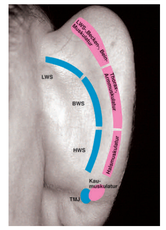

© 2016 VKM, München • Dr. med. Hans Garten
ISBN 978-3-9814333-1-9

5 Shu-Punkte; B&E-Punkte und NL-Reflexpunkte

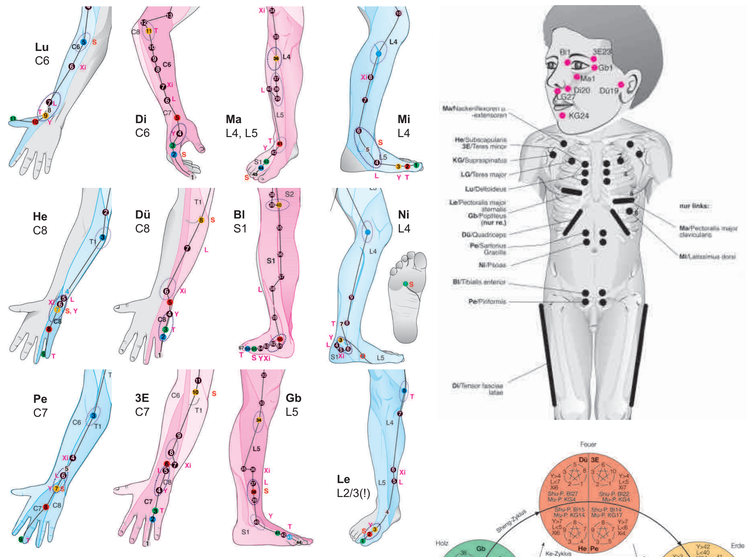

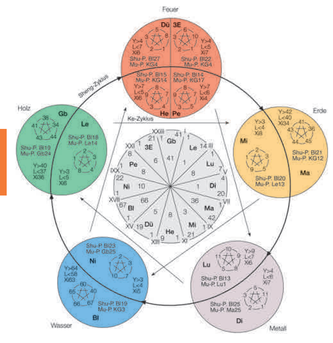

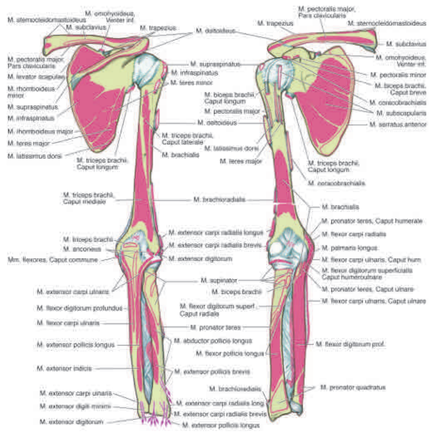

Handgelenk

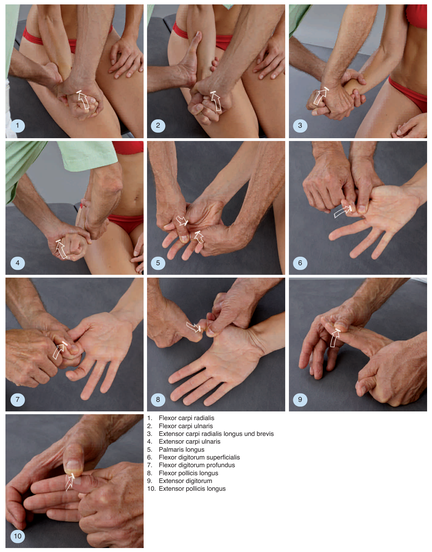

1. Flexor carpi radialis
2. Flexor carpi ulnaris
3. Extensor carpi radialis longus und brevis
4. Extensor carpi ulnaris
5. Palmaris longus
6. Flexor digitorum superficialis
7. Flexor digitorum profundus
8. Flexor pollicis longus
9. Extensor digitorum
10. Extensor pollicis longus

Ellbogen

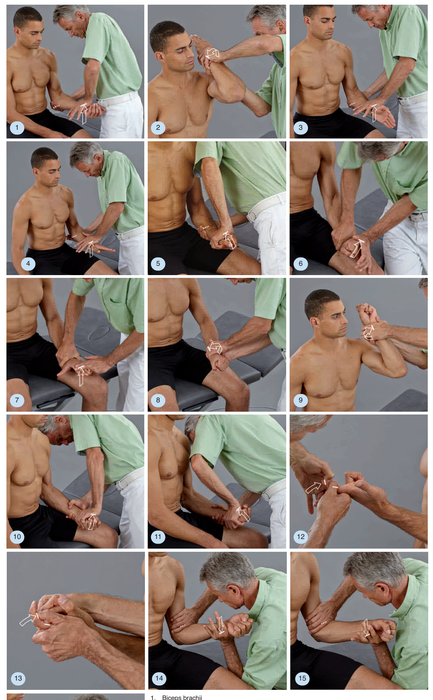

1. Biceps brachii
2. Supinator
3. Brachialis
4. Brachioradialis
5. Extensor carpi radialis
6. Extensor carpi ulnaris
7. Extensor digitorum
8. Pronator teres
9. Pronator quadratus
10. Flexor carpi radialis
11. Flexor carpi ulnaris
12. Flexor digitorum superficialis
13. Flexor digitorum profundus
14. Triceps brachii, Caput laterale
15. Triceps brachii, Caput longum
16. Triceps brachii, Caput mediale

Hand

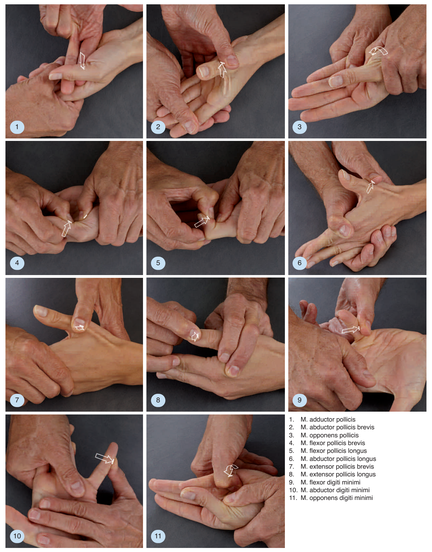

1. M. adductor pollicis
2. M. abductor pollicis brevis
3. M. opponens pollicis
4. M. flexor pollicis brevis
5. M. flexor pollicis longus
6. M. abductor pollicis longus
7. M. extensor pollicis brevis
8. M. extensor pollicis longus
9. M. flexor digiti minimi
10. M. abductor digiti minimi
11. M. opponens digiti minimi

Muskel	Organ (Sed.-P.)	Motorisches Segment, Nerv	Viszero-pyramidal
Abdominalmuskeln	Dünndarm (Dü8)	Th 5–Th12	Th 6,7
Adduktoren	Gonaden (Pe7)	L2–L5; Nn. obturatorius, (femor., ischiad.)	L5
Abductor pollicis brevis		C6, C7; N. medianus	
Adductor pollicis		C8, Th1; N. ulnaris	
Beckenbodenmuskeln		S(2), S3, S4; Rr. ant. Nn. sacrales II–IV	
Biceps brachii	Magen (Ma45)	C5, C6; N. musculocutaneus	
Brachialis	Magen (Ma45)	C5, C6; N. musculocutaneus	
Brachioradialis	Magen (Ma45)	C5, C6; N. radialis	
Coracobrachialis	Lunge (Lu5)	C6, C7; N. musculocutaneus	
Deltoideus	Lunge (Lu5)	C5, C6; N. axillaris	
Diaphragma	KG	C3–C5; N. phrenicus	Th5/6
Extensor carpi rad. long. u. brev.		C5–C7; N. radialis	
Extensor carpi ulnaris		C6–C8; N. radialis	
Extensor digitorum		C6–C8; N. radialis	
Extensor digitorum longus	Blase (Bl65)	L4, L5, S1; N. peroneus prof.	
Extensor pollicis long. u. brev.		C6–C8; N. radialis	
Flexor carpi radialis		C6–C8; N. medianus	
Flexor carpi ulnaris		C7, C8, Th1; N. ulnaris	
Flexor digitorum superficialis		C7, C8, Th1; N. medianus	
Flexor digitorum profundus		C7, C8, Th1; N. medianus, N. ulnaris	
Flexor hallucis brevis		S1, S2; N. plantaris (N. tibialis)	
Flexor hallucis longus		L5, S1, S2; N. tibialis	
Gluteus maximus	Gonaden (Pe7)	L5, S1, S2; N. gluteus inferior	L3
Gluteus medius	Gonaden (Pe7)	L4, L5, S1; N. gluteus superior	L5
Gracilis	Nebenniere (Pe7)	L2–L4; N. obturatorius	Th9
Hamstrings	Dickdarm (Di2)	L4, L5, S2; S2; N. ischiadicus	L1
Infraspinatus	Thymus (3E10)	C4–C6; N. suprascapularis	
Latissimus dorsi	Pankreas (Ma5)	C6–C8; N. thoracodorsalis	Th6
Levator scapulae	Parathyroid. (Lu5)	C3–C5; N. dorsalis scapulae	
Nackenextensoren	NNH (Ma45)	C2–C8; Nn. cervicales, Rami posteriores	
Nackenflexoren	NNH (Ma45)	C1–C8; Nn. cervicales, Rami anteriores	
Obturatorius internus	Gonaden (Pe7)	L5, S1, S2; Plexus sacralis	
Opponens pollicis		C6, C7; N. medianus	
Pectoralis major clavicularis	Magen (Ma45)	C5–C7; Nn. pectorales	Th5
Pectoralis major sternalis	Leber (Le2)	C6–C8, Th1; Nn. pectorales	Th8
Pectoralis minor		C6–C8, Th1; Nn. pectorales mediales	
Peroneus longus, brevis	Blase (Bl65)	L4, L5, S1; N. peroneus superficialis	
Peroneus tertius	Blase (Bl65)	L5, S1; N. peroneus profundus	
Piriformis	Gonaden (Pe7)	L5, S1, S2; Plexus sacralis	L5
Popliteus	Galleninfl. (GB39)	L4, L5, S1; N. tibialis	Th4
Pronator quadratus	Magen (Ma45)	C7, C8, Th1; N. medianus	
Pronator teres	Magen (Ma45)	C6, C7; N. medianus	
Psoas, Iliacus	Niere (Ni1)	L1–L4; Plexus lumbalis	Th11/12
Quadratus lumborum	Dickdarm (Di2)	Th12; L1–L3; Plexus lumbalis	L2
Quadriceps	Dünndarm (Dü8)	L2–L4; N. femoralis	Th10
Rhomboidei	Leber (Le2)	C4, C5; N. dorsalis scapulae	
Sartorius	Nebenniere (Pe7)	L2, L3; N. femoralis	Th9
Serratus anterior	Lunge (Lu5)	C5–C7; N. thoracicus longus	Th3
Sternocleidomastoideus	NNH (Ma45)	N. XI; C2, C3	
Subclavius		C5, C6; N. subclavius	
Subscapularis	Herz (He7)	C5–C7; N. subscapularis	Th2
Supinator	Magen (Ma45)	C5, C6; N. radialis	
Supraspinatus	Gehirn (KG)	C4–C6: N. suprascapularis	
Tensor fasciae latae	Dickdarm (Di2)	L4, L5, S1; N. gluteus superior	L4
Teres major	Wirbelsäule (LG)	C5–C7; N. subpularis	
Teres minor	Thyroidea (3E10)	C5, C6; N. axillaris	
Tibialis anterior	Blase (Bl65)	L4, L5, S1; N. peroneus profundus	
Tibialis posterior	Nebenniere (Pe7)	L5, S1; N. tibialis	
Trapezius; oberer	Auge, Ohr (Ni1)	N. XI; Nn. cervicales 2–4	
Trapezius; mittlerer, unterer	Milz (Ms5)	N. XI; Nn. cervicales 2–4	Th7
Triceps brachii	Pankreas (Ms5)	C6–C8, Th1; N. radialis	
Triceps surae	Nebenniere (Pe7)	L4, L5, S1; S2; N. tibialis	

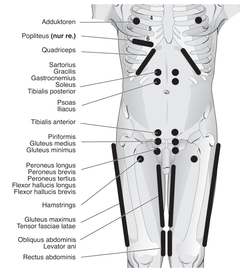

NL-Reflexzonen für Bein/Rumpf

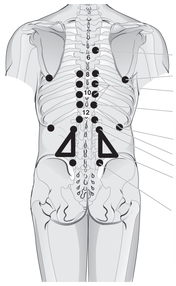

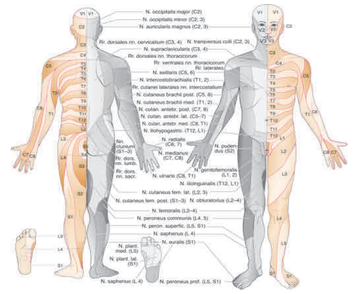

Hüfte, Becken, Bauch

1. M. rectus femoris
2. M. psoas
3. M. iliacus
4. M. pectineus
5. M. adductor longus, adductor brevis
6. M. adductor magnus, kraniale, ventrale Fasern
7. M. gracilis
8. M. tensor fasciae latae
9. M. gluteus medius und minimus
10. M. sartorius
11. M. piriformis (Rückenlage)
12. M. obturatorius internus und externus
13. Hamstrings (Rückenlage)
14. M. gluteus maximus
15. Hamstrings (Bauchlage)
16. M. adductor magnus, ischiokruraler Teil
17. M. piriformis (Bauchlage)
18. M. quadratus femoris
19. M. ischiococcygeus
20. M. iliococcygeus
21. M. pubococcygeus
22. M. obliquus internus abdominis
23. M. obliquus externus abdominis
24. M. quadratus lumborum

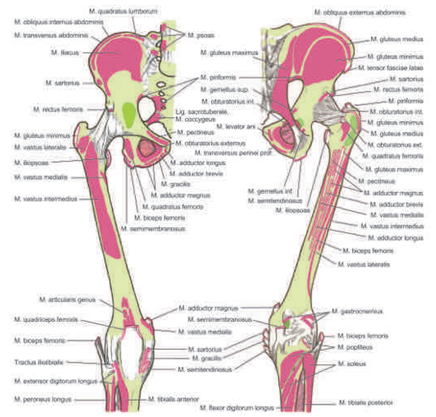

Knie

1. M. rectus femoris, Standard
2. Gestreckter Rektustest als Funktionstest des Patellagleitlagers
3. Distaler Rektustest, Funktionstest des M. vastus medialis (Patellaführung)
4. M. vastus medialis
5. Vastus intermedius bzw. Quadriceps global
6. Vastus lateralis
7. M. sartorius
8. M. gracilis (Rückenlage)
9. M. tensor fasciae latae
10. M. popliteus
11. M. biceps femoris
12. Lateraler Gastrocnemiuskopf
13. M. semimembranosus, M. semitendinosus (Rückenlage)
14. Medialer Gastrocnemiuskopf
15. M. biceps femoris
16. M. semimembranosus, M. semitendinosus (Bauchlage)
17. M. gracilis (Bauchlage)

Fuß

1. M. tibialis anterior
2. M. tibialis posterior
3. M. peroneus tertius, M. extensor digit. longus
4. M. peroneus long. und brev.
5. M. gastrocnemius, Caput mediale
6. M. gastrocnemius, Caput laterale
7. M. soleus
8. M. extensor hallucis longus
9. M. extensor hallucis brevis
10. M. flexor hallucis longus
11. M. flexor hallucis brevis
12. M. flexor digitorum longus

© 2016 VKM, München • Die Abbildungen sind folgenden Werken entnommen: „APPLIED KINESIOLOGY - FUNKTIONELLE MYODIAGNOSTIK IN OSTEOPATHIE UND CHIROTHERAPIE", H. Garten, ELSEVIER • URBAN & FISCHER, München, 2016, ISBN 978-3-437-57980-6 und LEHRBUCH APPLIED KINESIOLOGY, 2. Aufl., H. Garten, ELSEVIER • URBAN & FISCHER, München, 2012, ISBN 978-3-437-56851-0